



# Histologic analyses on the response of the skin to 1,927-nm fractional thulium fiber laser treatment

In Ho Kwon, Youin Bae, Un-Cheol Yeo, Jin Yong Lee, Hyuck Hoon Kwon, Young Hee Choi & Gyeong-Hun Park

To cite this article: In Ho Kwon, Youin Bae, Un-Cheol Yeo, Jin Yong Lee, Hyuck Hoon Kwon, Young Hee Choi & Gyeong-Hun Park (2018) Histologic analyses on the response of the skin to 1,927-nm fractional thulium fiber laser treatment, Journal of Cosmetic and Laser Therapy, 20:1, 12-16, DOI: [10.1080/14764172.2017.1358455](https://doi.org/10.1080/14764172.2017.1358455)

To link to this article: <https://doi.org/10.1080/14764172.2017.1358455>



Accepted author version posted online: 28 Jul 2017.  
Published online: 20 Sep 2017.



[Submit your article to this journal](#)



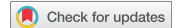Article views: 73



[View related articles](#)



[View Crossmark data](#)



## Histologic analyses on the response of the skin to 1,927-nm fractional thulium fiber laser treatment

In Ho Kwon<sup>a</sup>, Youin Bae<sup>b</sup>, Un-Cheol Yeo<sup>c</sup>, Jin Yong Lee<sup>d</sup>, Hyuck Hoon Kwon<sup>e</sup>, Young Hee Choi<sup>f</sup>, and Gyeong-Hun Park<sup>b</sup>

<sup>a</sup>PHD Dermatology Clinic, Seoul, Korea; <sup>b</sup>Department of Dermatology, Dongtan Sacred Heart Hospital, Hallym University College of Medicine, Hwaseong, Korea; <sup>c</sup>S&U Dermatologic Clinic, Seoul, Korea; <sup>d</sup>Department of Dermatology, Kangwon National University Hospital, Chuncheon, Korea; <sup>e</sup>Oaro Dermatology Clinic, Seoul, Korea; <sup>f</sup>Department of Pathology, Dongtan Sacred Heart Hospital, Hallym University College of Medicine and Research Institute for Complementary & Alternative Medicine, Hallym University, Hwaseong, Korea

### ABSTRACT

**Background:** The histologic responses to varied parameters of 1,927-nm fractional thulium fiber laser treatment have not yet been sufficiently elucidated. **Objective:** This study sought to evaluate histologic changes immediately after 1,927-nm fractional thulium fiber laser session at various parameters. **Methods:** The dorsal skin of Yucatan mini-pig was treated with 1,927-nm fractional thulium fiber laser at varied parameters, with or without skin drying. The immediate histologic changes were evaluated to determine the effects of varying laser parameters on the width and the depth of treated zones. **Results:** The increase in the level of pulse energy widened the area of epidermal changes in the low power level, but increased the dermal penetration depth in the high power level. As the pulse energy level increased, the increase in the power level under the given pulse energy level more evidently made dermal penetration deeper and the treatment area smaller. Skin drying did not show significant effects on epidermal changes, but evidently increased the depth of dermal denaturation under both high and low levels of pulse energy. **Conclusion:** These results may provide important information to establish treatment parameters of the 1,927-nm fractional thulium fiber laser for various skin conditions.

### ARTICLE HISTORY

Received 8 February 2017  
Accepted 17 July 2017

### KEYWORDS

1,927-nm thulium laser;  
fractional laser; histology;  
laser tissue interactions

### Introduction

The 1,927-nm laser has high absorption in water and delivers energy to both the epidermis and the upper dermis (1). As the laser can target dermal as well as epidermal lesions, it can improve not only epidermal processes including pigmentation but also dermal conditions with induction of collagen regeneration (1). Previous clinical studies of the 1,927-nm fractional thulium fiber laser have demonstrated its effectiveness in the treatment of pigment disorders including melisma (1–5), lentiginos (5,6), and postinflammatory hyperpigmentation (7), and other superficial lesions including seborrheic keratosis (8), actinic keratosis (9), and disseminated superficial actinic porokeratosis (10). Furthermore, several studies have also shown that the laser improves photoaging (6), wrinkling (1,3,5,6), skin laxity (1) and texture (3), enlarged skin pores (3), and scar (11), which seems to result from the dermal effect of the laser.

Over the years, the 1,927-nm thulium laser has been applied to clinical practice in dermatology using a fractional device (1,3–14). The treatment setting of the device has been based on the pulse energy level, and neither the level of power nor pulse duration could be modified by surgeons. However, a novel 1,927-nm fractional thulium fiber laser device that allows

controlling the power level and pulse duration separately has been introduced recently.

Considering that the 1,927-nm laser device can be used for a variety of indications including both epidermal and dermal conditions, an optimal parameter for each condition should be determined. However, there have not yet been studies on the histologic responses to varied parameters of 1,927-nm fractional laser treatment. Thus, this study sought to evaluate histologic changes immediately after 1,927-nm fractional thulium fiber laser session at various parameters.

### Materials and methods

A female Yucatan mini-pig was used for the study. The pig was acclimatized for 1 week prior to procedures. All procedures were performed according to the normal light cycle of the animal, and food was not given for 12 hours prior to procedures. Prior to procedures, the pig received general anesthesia with orotracheal intubation, and twelve 4 × 4 cm<sup>2</sup> areas were marked on the back of the animal. Hairs on the test sites were shaved using electric clippers, and then the topical anesthetic cream (EMLA® 5% cream, AstraZeneca, Södertälje, Sweden) was applied. The area was washed with water after 30 minutes.

**CONTACT** Gyeong-Hun Park, MD, PhD ✉ [borelgebra@gmail.com](mailto:borelgebra@gmail.com) 📧 Department of Dermatology, Dongtan Sacred Heart Hospital, Hallym University College of Medicine, 7, Keunjaebong-gil, Hwaseong-si, Gyeonggi-do, 18450, Republic of Korea; Young Hee Choi, MD, PhD ✉ [hopechoiq@naver.com](mailto:hopechoiq@naver.com) 📧 Department of Pathology, Dongtan Sacred Heart Hospital, Hallym University College of Medicine and Research Institute for Complementary & Alternative Medicine, Hallym University, 7, Keunjaebong-gil, Hwaseong-si, Gyeonggi-do, 18450, Republic of Korea.

In Ho Kwon and Youin Bae contributed equally to this work.

Color versions of one or more of the figures in the article can be found online at [www.tandfonline.com/ijcl](http://www.tandfonline.com/ijcl).

Treatments were performed using a 1,927-nm fractional thulium fiber laser device (Lavieen™, Won Tech Co., Ltd., Daejeon, Korea) and delivered to the mapped test sites on the back at various parameters indicated in Table 1. Just before the laser treatment, the skin within areas 10 and 11 was dried with a hair dryer.

To examine histologic changes after the laser treatments, 4-mm punch biopsies were taken immediately after treatment. Immediately after biopsies, the obtained tissue samples were fixed in formalin overnight and then embedded in paraffin. The samples were cut into slices, stained with hematoxylin and eosin, and then imaged using a light microscope. From the stained sections, the dimensions of individual treated zones were determined. The dimensions represent the width of the affected epidermis and the depth of the denatured dermis.

Linear effect models were fitted to evaluate the effects of varying laser parameters including levels of pulse energy and power, pulse stacking, and skin drying on the dimensions of treated zones. The means of each level of the factors were compared with adjustment

for multiple testing using false discovery rate correction. The data were analyzed using statistical software R version 3.3.1 (The R Foundation for Statistical Computing, Vienna, Austria), and a  $p$ -value of  $<0.05$  was considered statistically significant.

## Results

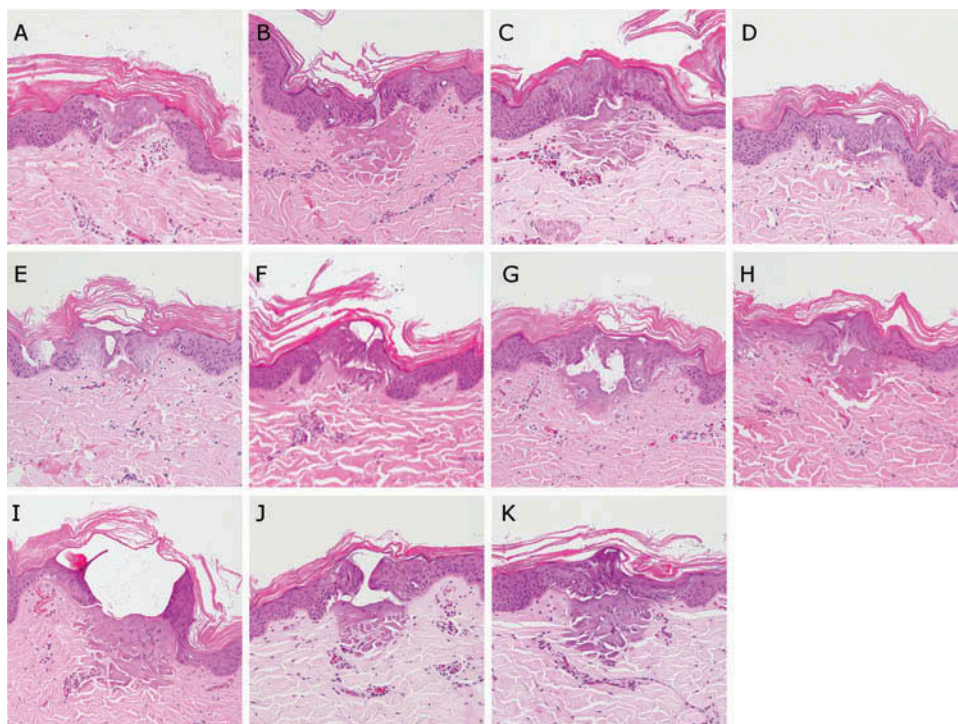
The 1,927-nm fractional thulium fiber laser produced a pattern of microscopic spots surrounded by unaffected normal skin. The representative histology is shown in Figure 1. Histologic examinations of individual laser-treated zones revealed relatively intact stratum corneum, coagulation necrosis of epidermal cells, and well-defined intraepidermal and dermoepidermal clefts. The clefts were surrounded by the overlying stratum corneum, necrotic epidermal cells, and denatured areas of the upper dermis.

### Effects of the level of pulse energy on the epidermal change and dermal denaturation

At the low power level (5 W), the width of the affected epidermis was significantly affected by the level of pulse energy ( $p < 0.01$ ). The width of the epidermal change was largest at the highest level of pulse energy, and smallest at the lowest level of pulse energy (Table 2, and Figure 1D, 1F, and 1G). However, the depth of the denatured dermis was not significantly changed according to the level of pulse energy ( $p = 0.14$ ). In contrast, at the high power level (10 W), the depth of the dermal denaturation was significantly affected by the level of pulse energy ( $p < 0.01$ ). The dermal depth was largest at the highest level of pulse energy and smallest at the lowest level of pulse energy (Table 2, and Figure 1A, 1C, and 1E). However, the epidermal width was not significantly changed according to the level of pulse energy ( $p = 0.22$ ).

**Table 1.** Laser parameters for treatment areas.

Area	Power (W)	Duration (msec)	Stack number	Drying
1	10	1	1	No
2	10	1.6	1	No
3	10	2	1	No
4	5	2	1	No
5	10	1.5	1	No
6	5	3	1	No
7	5	4	1	No
8	10	1	2	No
9	10	2	2	No
10	10	1	1	Yes
11	10	1.6	1	Yes



**Figure 1.** Histological appearance immediately after 1,927-nm fractional thulium fiber laser treatment at various parameters. The results at treatment areas 1–11 correspond to panels A–K respectively (hematoxylin and eosin stain; x100).

**Table 2.** Effects of the level of pulse energy on the epidermal change and dermal denaturation.

Power (W)	Energy (mJ)	Epidermal width ( $\mu\text{m}$ )		Dermal depth ( $\mu\text{m}$ )	
		Mean $\pm$ SE	<i>P</i>	Mean $\pm$ SE	<i>P</i>
5	10	195.2 $\pm$ 16.1	<0.01	44.8 $\pm$ 11.2	0.14
	15	256.1 $\pm$ 20.5		68.8 $\pm$ 3.8	
	20	403.0 $\pm$ 7.3		85.5 $\pm$ 8.8	
10	10	229.2 $\pm$ 20.4	0.22	33.0 $\pm$ 3.9	<0.01
	15	278.0 $\pm$ 9.4		96.1 $\pm$ 0.4	
	20	282.6 $\pm$ 15.3		176.2 $\pm$ 27.4	

### Effects of the level of power on the epidermal change and dermal denaturation

As the same level of pulse energy can be delivered in different ways by altering the level of power, it was assessed whether the tissue reaction is different or not according to the level of power under the given level of pulse energy. At the low level of pulse energy (10 mJ), neither the epidermal width nor the dermal depth was significantly affected according to the level of power ( $p = 0.33$  and  $p = 0.36$ , respectively; Table 3 and Figure 1A and 1D). At the intermediate level of pulse energy (15 mJ), the higher power level (10 W) induced significantly deeper dermal denaturation ( $p < 0.01$ ; Table 3 and Figure 1E and 1F), but the epidermal width was not significantly altered by the level of power ( $p = 0.42$ ). At the high level of pulse energy (20 mJ), the higher power level (10 W) made significantly narrower epidermal changes and deeper dermal denaturation ( $p < 0.01$  and  $p = 0.03$ , respectively; Table 3 and Figure 1C and 1G).

### Effects of pulse stacking on the epidermal change and dermal denaturation

At the low level of pulse energy (10 mJ per pulse), pulse stacking resulted in both wider epidermal changes and deeper dermal denaturation ( $p < 0.01$  for both; Table 4 and Figure 1A and 1H). In contrast, at the high level of pulse energy (20 mJ

**Table 3.** Effects of the level of power on the epidermal change and dermal denaturation.

Energy (mJ)	Power (W)	Epidermal width ( $\mu\text{m}$ )		Dermal depth ( $\mu\text{m}$ )	
		Mean $\pm$ SE	<i>P</i>	Mean $\pm$ SE	<i>P</i>
10	5	195.2 $\pm$ 16.1	0.33	44.8 $\pm$ 11.2	0.36
	10	229.2 $\pm$ 20.4		33.0 $\pm$ 3.9	
15	5	256.1 $\pm$ 20.5	0.42	68.8 $\pm$ 3.8	<0.01
	10	278.0 $\pm$ 9.4		96.1 $\pm$ 0.4	
20	5	403.0 $\pm$ 7.3	<0.01	85.5 $\pm$ 8.8	0.03
	10	282.6 $\pm$ 15.3		176.2 $\pm$ 27.4	

**Table 4.** Effects of pulse stacking on the epidermal change and dermal denaturation.

Pulse energy (mJ)	Stack number	Epidermal width ( $\mu\text{m}$ )		Dermal depth ( $\mu\text{m}$ )	
		Mean $\pm$ SE	<i>P</i>	Mean $\pm$ SE	<i>P</i>
10	1	229.2 $\pm$ 20.4	<0.01	33.0 $\pm$ 3.9	<0.01
	2	353.8 $\pm$ 5.1		152.2 $\pm$ 4.4	
20	1	282.6 $\pm$ 15.3	<0.01	176.2 $\pm$ 27.4	0.44
	2	470.6 $\pm$ 20.9		207.7 $\pm$ 17.2	

per pulse), the width of the epidermal changes was significantly increased by pulse stacking ( $p < 0.01$ ; Table 4 and Figure 1C and 1I), but the depth of dermal denaturation was not significantly affected by pulse stacking ( $p = 0.44$ ).

### Effects of skin drying on the epidermal change and dermal denaturation

At both the low level (10 mJ) and the high level (16 mJ) of pulse energy, skin drying significantly increased the depth of dermal denaturation ( $p < 0.01$  and  $p = 0.01$ , respectively; Table 5 and Figure 1A, 1B, 1J and 1K). In contrast, the width of epidermal changes was not significantly altered by skin drying at either the low level or the high level of pulse energy ( $p = 0.46$  and  $p = 0.10$ , respectively).

## Discussion

To the best of our knowledge, this is the first study on the histologic changes of the skin at various treatment parameters of the 1,927-nm fractional thulium fiber laser system. Although previous studies reported the reaction of the skin tissue to lasers with wavelengths of 1,940–2,000 nm, they used long pulse durations (10 msec–10 sec) and large diameters (0.48 cm–1.8 cm) (15–17). In clinical settings, however, only fractional devices have come into wide use for dermatologic applications of the 1,927-nm thulium laser (1,3–14). The previous studies using the nonfractional lasers cannot be directly applied to determine treatment parameters of the current fractional devices because of differences in pulse duration and beam diameter. Thus, our present study may provide important information to establish treatment parameters of the 1,927-nm fractional thulium fiber laser for various skin conditions.

This study confirmed the previous findings on the reaction of the skin to the 1,927-nm thulium laser. The 1,927-nm laser has high absorption coefficients for water, which results in higher absorption of laser energy in the dermis than the epidermis (17). Thus, the stratum corneum remains relatively intact, and the dermal penetration is limited within the superficial dermis (15,16,18). Consistent with these characteristics, this study also showed that the 1,927-nm fractional thulium fiber laser induces the epidermal necrosis sparing the stratum corneum and collagen denaturation at the upper dermis within the depth of 200  $\mu\text{m}$ .

In our present study, the effects of the pulse energy level on the skin changes were dependent on the level of power. The increase in the level of pulse energy primarily widened the area of epidermal changes in the low power level, but mainly increased the dermal penetration depth in the high power level. In addition, the

**Table 5.** Effects of skin drying on the epidermal change and dermal denaturation.

Energy (mJ)	Drying	Epidermal width ( $\mu\text{m}$ )		Dermal depth ( $\mu\text{m}$ )	
		Mean $\pm$ SE	<i>P</i>	Mean $\pm$ SE	<i>P</i>
10	No	229.2 $\pm$ 20.4	0.46	33.0 $\pm$ 3.9	<0.01
	Yes	250.0 $\pm$ 5.8		139.7 $\pm$ 1.5	
16	No	224.6 $\pm$ 12.6	0.10	152.9 $\pm$ 3.3	0.01
	Yes	322.0 $\pm$ 25.3		194.3 $\pm$ 7.9	



effects of the power level under the given level of pulse energy were also dependent on the level of pulse energy. As the pulse energy level increased, the increase in the power level under the given pulse energy level more evidently made dermal penetration deeper and the treatment area smaller. It means that if the same level of pulse energy is delivered, a higher power level results in more focal and deeper treatment effects and a longer pulse duration induces broader and more superficial effects in particular when the level of pulse energy is high. These findings suggest that the low energy level should be used to target epidermal lesions with minimizing dermal effects. To compensate the smaller area coverage of the low energy level, multipass treatments can be considered. If the high energy level should be applied necessarily, the low power level should be employed to reduce dermal changes. In contrast, to maximize the dermal penetration, a high level of pulse energy should be delivered at a high power level.

The device used in our present study allows separate manipulation of the power level and pulse duration, and thus they can be determined by users depending on the target. However, some fractional thulium fiber laser devices provide only controlling the level of pulse energy without allowing users to adjust the power level or pulse duration under the given energy level. To seek a way for users to more selectively target desired lesions using such devices, the effects of pulse stacking and skin drying on the laser tissue interaction were evaluated.

Pulse stacking increased both the width of epidermal changes and the depth of dermal denaturation under the low level of pulse energy. Considering that the low energy level is preferred to target epidermal lesions as discussed above, pulse stacking may induce unwanted dermal changes when targeting epidermal lesions. Furthermore, the depth of dermal denaturation was not affected by pulse stacking in the high level of pulse energy. Because the high pulse energy level should be used to target deeper dermal lesions, pulse stacking does not help increase the treatment effects when targeting dermal lesions. Consequently, pulse stacking is useful for selectively targeting neither epidermal nor dermal lesions.

Skin drying did not show significant effects on epidermal changes, but evidently increased the depth of dermal denaturation under both high and low levels of pulse energy. These findings may result from the high absorption rate of 1,927-nm laser for water. Thus, skin drying can be a useful maneuver to maximize the dermal effects of 1,927-nm fractional thulium fiber laser when difficult to change other treatment parameters.

This study has several limitations. First, this study used the porcine skin instead of the human skin. However, the porcine skin shows great similarities to the human skin in anatomical and physiological aspects (19). Previous studies on the fractional laser devices have also shown that the laser tissue interaction of the porcine skin is very close to that of the human skin (20,21). Second, this study evaluated the immediate reaction to the laser and thus cannot determine the long-term histologic changes after laser irradiation.

In conclusion, the 1,927-nm fractional thulium fiber laser induces epidermal changes and upper dermal tissue denaturation with relative sparing of the stratum corneum. As 1,927-nm thulium laser can make varied patterns according to the

treatment parameters, our results may be a useful consideration to determine the treatment strategy.

## Declaration of interest

The authors have no conflict of interest to declare.

## Funding

This research was supported by Hallym University Research Fund 2014 (HURF-2014-17).

## References

1. Lee HM, Haw S, Kim JK, Chang SE, Lee MW. Split-face study using a 1,927-nm thulium fiber fractional laser to treat photoaging and melasma in Asian skin. *Dermatol Surg*. 2013;39:879–88. doi:10.1111/dsu.12176.
2. Geddes ER, Stout AB, Friedman PM. Retrospective analysis of the treatment of melasma lesions exhibiting increased vascularity with the 595-nm pulsed dye laser combined with the 1927-nm fractional low-powered diode laser. *Lasers Surg Med*. 2017;49:20–26. doi:10.1002/lsm.22518.
3. Ho SG, Yeung CK, Chan NP, Shek SY, Chan HH. A retrospective study of the management of Chinese melasma patients using a 1927 nm fractional thulium fiber laser. *J Cosmet Laser Ther*. 2013;15:200–06. doi:10.3109/14764172.2012.761346.
4. Niwa Massaki AB, Eimpunth S, Fabi SG, Guiha I, Groff W, Fitzpatrick R. Treatment of melasma with the 1,927-nm fractional thulium fiber laser: a retrospective analysis of 20 cases with long-term follow-up. *Lasers Surg Med*. 2013;45:95–101. doi:10.1002/lsm.22100.
5. Polder KD, Bruce S. Treatment of melasma using a novel 1,927-nm fractional thulium fiber laser: A pilot study. *Dermatol Surg*. 2012;38:199–206. doi:10.1111/j.1524-4725.2011.02178.x.
6. Polder KD, Harrison A, Eubanks LE, Bruce S. 1,927-nm fractional thulium fiber laser for the treatment of nonfacial photodamage: A pilot study. *Dermatol Surg*. 2011;37:342–48. doi:10.1111/j.1524-4725.2011.01884.x.
7. Lee SJ, Chung WS, Lee JD, Kim HS. A patient with cupping-related post-inflammatory hyperpigmentation successfully treated with a 1,927 nm thulium fiber fractional laser. *J Cosmet Laser Ther*. 2014;16:66–68. doi:10.3109/14764172.2013.854121.
8. Polder KD, Mithani A, Harrison A, Bruce S. Treatment of macular seborrheic keratoses using a novel 1927-nm fractional thulium fiber laser. *Dermatol Surg*. 2012;38:1025–31. doi:10.1111/j.1524-4725.2012.02427.x.
9. Weiss ET, Brauer JA, Anolik R, Reddy KK, Karen JK, Hale EK, Brightman LA, Bernstein L, Geronemus RG. 1927-nm fractional resurfacing of facial actinic keratoses: A promising new therapeutic option. *J Am Acad Dermatol*. 2013;68:98–102. doi:10.1016/j.jaad.2012.05.033.
10. Ross NA, Rosenbaum LE, Saedi N, Arndt KA, Dover JS. Disseminated superficial actinic porokeratosis improved with fractional 1927-nm laser treatments. *J Cosmet Laser Ther*. 2016;18:53–55. doi:10.3109/14764172.2015.1063657.
11. Finney R, Torbeck R, Saedi N. Non-ablative fractional resurfacing in the treatment of scar contracture. *Lasers Surg Med*. 2016;48:170–73. doi:10.1002/lsm.v48.2.
12. Boen M, Wilson MJ, Goldman MP, Wu DC. Rejuvenation of the male scalp using 1,927 nm non-ablative fractional thulium fiber laser. *Lasers Surg Med*. 2017;49:475–79. doi:10.1002/lsm.22624.
13. Cohen SR, Goodacre A, Lim S, Johnston J, Henssler C, Jeffers B, Saad A, Leong T. Clinical outcomes and complications associated

- with fractional lasers: A review of 730 patients. *Aesthetic Plast Surg.* 2017;41:171–78. doi:[10.1007/s00266-016-0767-x](https://doi.org/10.1007/s00266-016-0767-x).
14. Lee SM, Kim MS, Kim YJ, Won CH, Lee MW, Choi JH, Moon KC, Chang SE. Adverse events of non-ablative fractional laser photothermolysis: A retrospective study of 856 treatments in 362 patients. *J Dermatolog Treat.* 2014;25:304–07. doi:[10.3109/09546634.2013.777151](https://doi.org/10.3109/09546634.2013.777151).
  15. Chen B, O'Dell DC, Thomsen SL, Rockwell BA, Welch AJ. Porcine skin ED50 damage thresholds for 2,000 nm laser irradiation. *Lasers Surg Med.* 2005;37:373–81. doi:[10.1002/lsm.20243](https://doi.org/10.1002/lsm.20243).
  16. Chen B, Thomsen SL, Thomas RJ, Oliver J, Welch AJ. Histological and modeling study of skin thermal injury to 2.0 microm laser irradiation. *Lasers Surg Med.* 2008;40:358–70. doi:[10.1002/lsm.20630](https://doi.org/10.1002/lsm.20630).
  17. Oliver JW, Stolarski DJ, Noojin GD, Hodnett HM, Harbert CA, Schuster KJ, Foltz MF, Kumru SS, Cain CP, Finkeldei CJ, Buffington GD, Noojin ID, Thomas RJ. Infrared skin damage thresholds from 1940-nm continuous-wave laser exposures. *J Biomed Opt.* 2010;15:065008. doi:[10.1117/1.3523622](https://doi.org/10.1117/1.3523622).
  18. Jacques SL. Role of tissue optics and pulse duration on tissue effects during high-power laser irradiation. *Appl Opt.* 1993;32:2447–54. doi:[10.1364/AO.32.002447](https://doi.org/10.1364/AO.32.002447).
  19. Summerfield A, Meurens F, Ricklin ME. The immunology of the porcine skin and its value as a model for human skin. *Mol Immunol.* 2015;66:14–21.
  20. Hantash BM, Bedi VP, Kapadia B, Rahman Z, Jiang K, Tanner H, Chan KF, Zachary CB. In vivo histological evaluation of a novel ablative fractional resurfacing device. *Lasers Surg Med.* 2007;39:96–107. doi:[10.1002/lsm.20468](https://doi.org/10.1002/lsm.20468).
  21. Skovbolling Haak C, Illes M, Paasch U, Haedersdal M. Histological evaluation of vertical laser channels from ablative fractional resurfacing: An ex vivo pig skin model. *Lasers Med Sci.* 2011;26:465–71. doi:[10.1007/s10103-010-0829-2](https://doi.org/10.1007/s10103-010-0829-2).